

blood

1968 32: 950-961

The May-Hegglin Anomaly: Platelet Function, Ultrastructure and Chromosome Studies

JEANNE M. LUSHER, JOHN SCHNEIDER, I. MIZUKAMI and RUTH K. EVANS

Information about reproducing this article in parts or in its entirety may be found online at:
http://bloodjournal.hematologylibrary.org/misc/rights.dtl#repub_requests

Information about ordering reprints may be found online at:
<http://bloodjournal.hematologylibrary.org/misc/rights.dtl#reprints>

Information about subscriptions and ASH membership may be found online at:
<http://bloodjournal.hematologylibrary.org/subscriptions/index.dtl>



The May-Hegglin Anomaly: Platelet Function, Ultrastructure and Chromosome Studies

By JEANNE M. LUSHER, JOHN SCHNEIDER, I. MIZUKAMI,
AND RUTH K. EVANS

THE MAY-HEGGLIN ANOMALY is a rare hereditary condition characterized by giant platelets and Döhle inclusion bodies in the granulocytes. May first described the anomaly in 1909,¹ and in 1945 Hegglin described the condition in a man and his two sons.² Subsequent reports have confirmed the familial nature with an autosomal dominant mode of inheritance.³⁻¹³

Although most persons with the May-Hegglin anomaly have no abnormal clinical manifestations, some have had a definite hemorrhagic tendency which would not be wholly accounted for by the degree of thrombocytopenia which they manifested. Detailed coagulation studies have been reported in only two instances.^{4,11} Three affected members of one family were found to have a moderate deficiency of platelet thromboplastic activity;⁴ electron microscopic observations of whole unsectioned platelets of one member of this family were interpreted as demonstrating abnormal viscous metamorphosis.¹⁴

We have recently had the opportunity to study a father and son with the May-Hegglin anomaly. The present report describes coagulation studies, particularly those of platelet function, as well as electron microscopic observations of platelet and granulocyte ultrastructure. Chromosomal studies are included as the only previous report of chromosome analysis in the May-Hegglin anomaly described a minor chromosomal abnormality.⁷

CASE REPORT

The father reported here and his brother, both physicians, were found to have the May-Hegglin anomaly on incidental examination of their peripheral blood smears. Both were clinically well. The father studied by us underwent a tonsillectomy and adenoidectomy at age eight years without excessive bleeding, and has had no bleeding manifestations other than a bleeding peptic ulcer at age 30, which was controlled with diet and antacids. When peripheral blood smears were obtained on his two sons, one and one-half and four years old, the oldest son was found to have Döhle bodies and giant platelets, while the younger boy did not.

The family is of German and Irish descent. The physicians' parents were unavailable for study, and it is not known whether either parent had the May-Hegglin anomaly.

From The Child Research Center of Michigan and the Children's Hospital of Michigan, Detroit, Michigan.

Supported by a grant from the Children's Leukemia Foundation.

First submitted December 5, 1967; accepted for publication March 31, 1968.

JEANNE M. LUSHER, M.D.: *Associate Hematologist, Children's Hospital of Michigan; Assistant Professor of Pediatrics, Wayne State University School of Medicine.* JOHN R. SCHNEIDER, M.D.: *Clinical Instructor of Medicine, Wayne State University School of Medicine.* I. MIZUKAMI, PH.D.: *Research Associate, Child Research Center of Michigan.* RUTH K. EVANS, B.S.: *Research Associate, Child Research Center of Michigan.*

METHODS

Peripheral blood films were stained with Wright's stain. Platelet counts were done by the direct method, using a phase contrast microscope. Platelet rich plasma (PRP) for platelet function tests was prepared by collecting blood in one-tenth volume 3.8 per cent sodium citrate and allowing it to stand at 4 C. for two to three hours until erythrocytes had settled out. (This method of processing was found to be necessary, as with the slow speed centrifugation routinely used for obtaining PRP the giant platelets were spun down with the red cells.) PRP was pipetted off and maintained in silicone glassware at 4 C. and tests performed as soon as possible. In order to avoid erythrocyte contamination only the upper third of the PRP was used. All *in vitro* microscopic observations were made on citrated PRP at room temperature using a phase contrast microscope.

Ultrastructural Studies

Sectioned platelets and granulocytes were studied with the electron microscope. Venous blood was collected into ACD solution in siliconized tubes and allowed to settle.

The buffy coat (containing platelets and WBC's) was processed in the following manner:
1) Fixed in 2.5 per cent glutaraldehyde¹⁵ in Millonig's buffer¹⁶ for 2 hours at room temperature.

2) Washed several times with the buffer over a period of several hours, to remove unbound glutaraldehyde.

3) Stored at 4 C. in buffer for three days.

4) Post-fixed in Palade's fixative¹⁷ for 2 hours at room temperature.

5) Embedded in 2 per cent agar at 45-50 C.¹⁸

6) Agar blocks were dehydrated with acetone.

7) Blocks were embedded in Vestopal-W¹⁹ polymerized for 24 hours at 60 C. in BEEM capsules.

8) Sections were cut on an LKB Ultratome, type 8801A, using glass knives.

9) Staining of sections was accomplished with uranyl acetate or uranyl acetate and lead citrate.²⁰

10) Stained sections were examined by means of an RCA-EMU3H electron microscope at 50 KV.

Tests of Platelet Function

Macroscopic platelet aggregation in citrated PRP was estimated in glass tubes after addition of ADP (1.0 to 60 µg per cc.) and adrenalin (1.0 µg per cc.).²¹ The tubes were agitated and observed through a hand lens for platelet clumping. PRP was also observed microscopically for the presence of spontaneous aggregation and adhesion.²² Samples of PRP were mixed with ADP, adrenalin, and a semipurified collagen preparation (saline extract of human dura) and observed for microscopic aggregation and adhesion.^{23,24}

Platelet adhesiveness was done by two methods: A). a modification of the *in vitro* method of Salzman, in which venous blood is passed through a standard glass bead column and the percentage of platelets which adhere to the glass beads is determined by comparison of direct platelet counts done before and after passage through the beads;²⁵ and B). *in vivo* platelet adhesiveness as determined by the method of Borchgrevink,²⁶ in which the difference in platelet count between a venous sample and a "capillary" blood sample from a standard wound represents the adhesive platelets.

The release of platelet aggregating activity (platelet release phenomenon) was tested as follows. Citrated PRP was defibrinated with thrombin or agitated with a tendon extract for four minutes. The supernatant plasma was separated by centrifugation at 3000 g. and an aliquot tested for macroscopic aggregating activity on normal citrated PRP.²⁷

General Tests of Hemostatic Function

These tests included the Ivy bleeding time, tourniquet test, Lee-White clotting time, Quick prothrombin time and serum prothrombin time.²⁸⁻³¹ The hemolysate prothrombin consumption time was determined by the method of Quick.³²

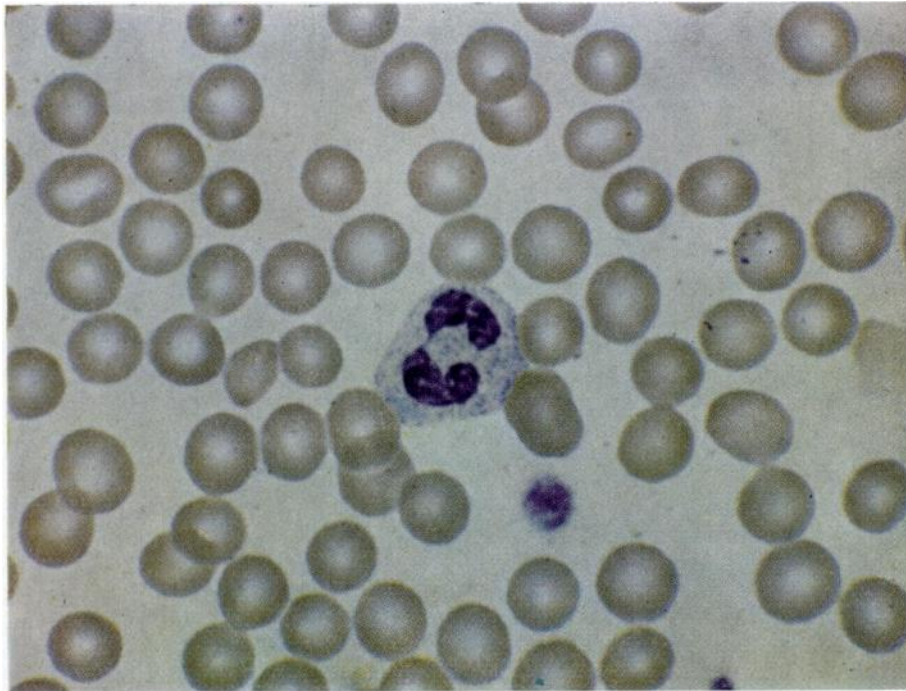


Fig. 1.—Father's peripheral blood smear showing giant platelet and pale blue Döhle body in cytoplasm of neutrophil.

Platelet Thromboplastic Activity

The father's washed platelets were compared to normal platelets in the T.G.T. system, using normal serum and normal adsorbed plasma. Test and control platelets were washed three times in normal saline and tested at four different concentrations.

Other Studies

Chromosome preparations were made from peripheral blood leukocyte cultures. Serum immunoelectrophoresis was done by the method of Heimburger and Schwick.³³

OBSERVATIONS AND RESULTS

Wright's stained peripheral blood films from father and son showed, in addition to a lesser number of smaller, normal appearing platelets, marked variation in size and shape of platelets, with many giant round forms and elliptical forms measuring up to $8\ \mu$ (Fig. 1). Döhle bodies were easily visible in the cytoplasm of 98 per cent of the granulocytes and 50 per cent of monocytes. They appeared as fusiform or crescentic inclusions near the periphery, most measuring one to three μ in diameter and staining a prominent sky blue color against the pinkish gray background of the neutrophilic cytoplasm. While most granulocytes contained one Döhle body, some contained two or three. They were also visible in the eosinophils and basophils, although almost obscured by the coarser granules.

The father is mildly thrombopenic, while his affected son has a normal plate-

Table 1.—Platelet Studies

Test	Father	Son
Direct Platelet Count (Normal 160,000-400,000)	100,000/mm. ³	328,000
Morphology—Light & Phase Microscopy	Marked variation in size and shape, with many giant platelets	Same
Electron Microscopy	Normal ultrastructural appearance	Not done
Clot retraction	Good	Good
Serum Prothrombin Time (Normal >25 seconds)	14 seconds	32 seconds
Serum Prothrombin Time with Hemolysate (Normal >45 seconds)	46 seconds	—
Ivy Bleeding Time (Normal 3 to 7 minutes)	6 minutes	Not done
Tourniquet Test	Negative	Negative
Platelet Adhesiveness (Normal >20 per cent)	36 per cent	64 per cent
Platelet Thromboplastic Function (T.G.T.)	Abnormal	Not done
Aggregation by ADP	Normal	Normal
Aggregation by Adrenalin	Normal	Normal
Aggregation by Collagen	Normal	Normal
Adherence to Connective Tissue Particles	Normal	Normal
Release of Platelet Aggregating Activity	Normal	Normal

let count (Table 1). Under phase microscopy the platelets of both father and son again showed considerable variation in size and shape with many giant forms, but otherwise appeared normal.

Ultrastructural Observations

Electron microscopy of the father's sectioned platelets revealed them to be quite large, but ultrastructurally normal. Specific granules, mitochondria and other organelles were similar to those of normal platelets. The granulocytes had irregular cytoplasmic regions which lacked specific granules (Figs. 2 and 3). These regions correspond in size and shape to the Döhle bodies seen with light microscopy of Wright's stained blood films. The cytoplasmic patches are distinctly separated from the surrounding cytoplasm; and consist of small granules, homogeneous amorphous densities, and fine electron-dense fibrils of various lengths.

Tests of Platelet Function and General Hemostatic Function

Macroscopic platelet aggregation occurred normally on addition of ADP, adrenalin, and collagen preparation. After addition of ADP to father's and son's PRP, sudden massive clumping occurred within ten seconds. Similarly, adrenalin induced aggregation within 20 seconds, and a saline extract of human dura also clumped the platelets within 20 seconds.

When PRP was observed by phase microscopy, spontaneous aggregation on a glass slide occurred normally, as did rapid microscopic aggregation following addition of ADP, adrenalin, or collagen preparation. There was also normal adhesion to the collagen particles.

Platelet adhesiveness was found to be normal. The consumption of the

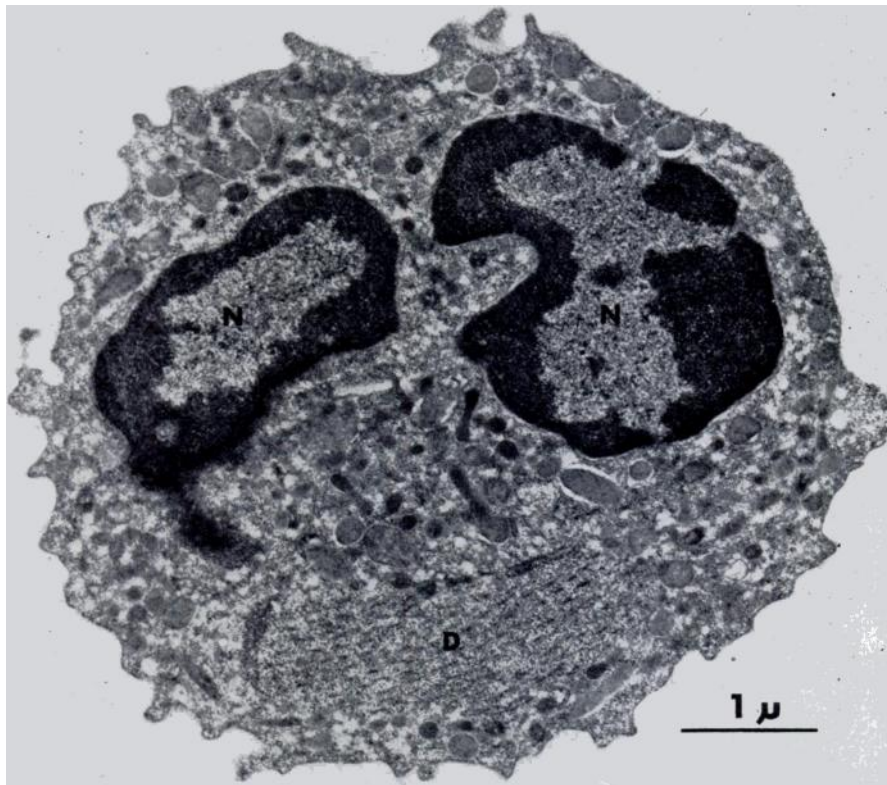


Fig. 2.—Ultrastructure of neutrophil, showing irregular cytoplasmic region which lacks specific granules. Glutaraldehyde-osmium tetroxide fixation, section stained with uranyl acetate and lead citrate. Original magnification 28,000. N = nucleus, D = Döhle body.

father's platelets on glass beads was 36 per cent (normal > 20 per cent), and that of the son's platelets 64 per cent. In vivo platelet adhesiveness test demonstrated adherence of 70 per cent of the father's platelets to the damaged vessel wall.

Release of platelet aggregating activity was also normal. The supernatant plasma removed 15 minutes after addition of thrombin gave normal substrate aggregation times of approximately nine seconds. Similar results were obtained in PRP treated with a tendon extract.

General tests of hemostatic function in the father revealed a Lee-White clot-

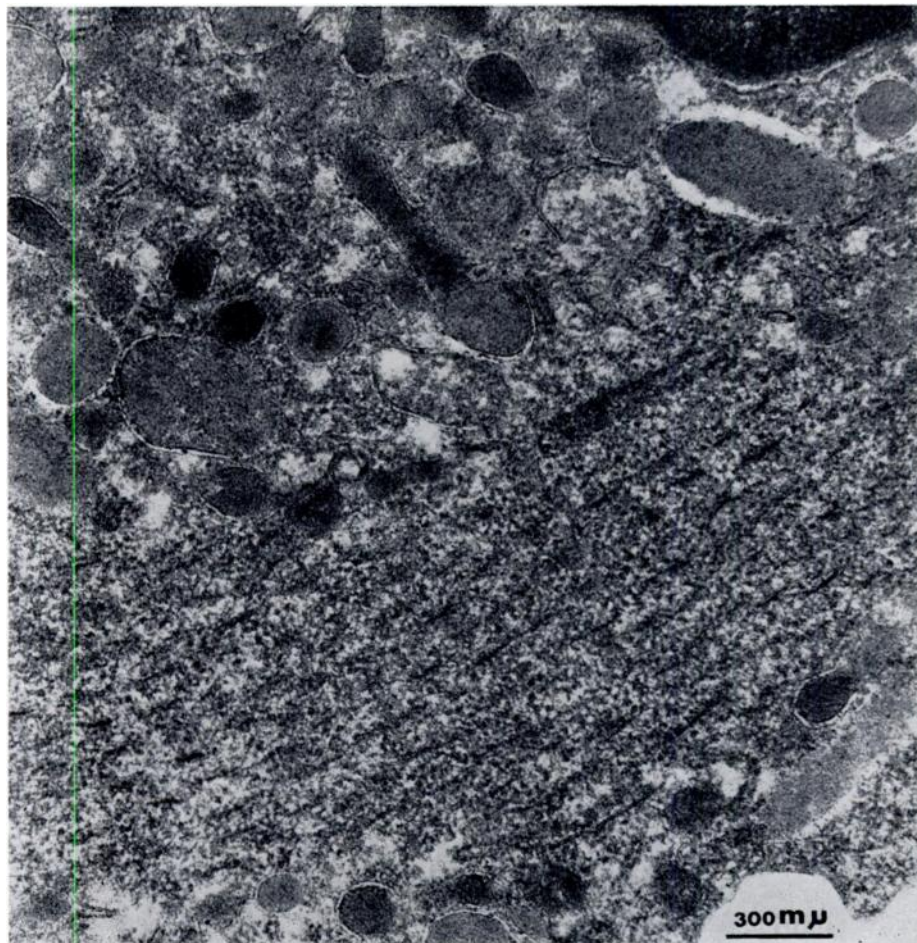


Fig. 3.—Higher magnification of Döhle body from Figure 2 showing particles of various sizes, and fine electron-dense fibrils. Original magnification 72,500.

ting time of 14 minutes (normal, ten to fifteen minutes), good clot retraction at one hour, negative tourniquet test, Ivy bleeding time of six minutes (normal, three to seven minutes), Quick prothrombin time of 12.8 seconds (control 12.6 seconds), Owren prothrombin assay 100 per cent, factor V assay 100 per cent, and partial thromboplastin time, 66 seconds (normal, 60 to 70 seconds).

The father's serum prothrombin time was determined on three separate occasions and found to be 14.2, 14.7 and 15.0 seconds (normal, > 25 seconds). These abnormally short serum prothrombin times were corrected to 46–48 seconds by the addition of hemolysate. When his washed platelets were tested with normal adsorbed plasma and normal serum in the T.G.T., a definite lag was observed with platelet concentrations of 125,000 and 250,000/mm.³, suggesting a moderate defect of platelet thromboplastic function (Table 2).

The son also had a normal clotting time, good clot retraction, and negative

Table 2.—Platelet Thromboplastic Function*

Incubation Time (minutes)	1,000,000 Pl./mm. ³		500,000 Pl./mm. ³		250,000 Pl./mm. ³		125,000 Pl./mm. ³	
	Father	Control	Father	Control	Father	Control	Father	Control
1	9	19	11	9	27	18	56	36
2	8	8	9	8	12	9	13	10
3	10	8	8	8	15	10	16	10
4	11	8	10	9	15	11	17.6	13
5	12	8	11	10	16	11	18	14

*Father's platelets and control platelets tested at 4 concentrations; father's platelets show a lag at concentrations of 125,000 and 250,000/mm.³ The same Normal adsorbed plasma and serum were used in all test systems.

tourniquet test. His serum prothrombin time was normal, being 32 seconds. Not enough blood was obtained to test his platelets in the T.G.T. system.

Chromosomes and Immunoglobulins

Both father and son had a normal modal number of 46 chromosomes with a normal karyotype. Immunoelectrophoresis of their sera revealed normal patterns.

DISCUSSION

In 1912 Döhle described oval blue-staining cytoplasmic inclusions in the leucocytes of patients with scarlet fever.³⁴ They were later noted to occur transiently in the acute phase of other infectious diseases (erysipelas, rubeola, typhus, tuberculosis, diphtheria, as well as infections with *E. coli*, *Pseudomonas*, and *Staphylococcus aureus*).³⁵⁻³⁸ They are usually round or oval, and vary in size from just visible to one to two μ in diameter. Döhle bodies are a frequent finding in the granulocytes of patients with burns involving more than two per cent full thickness skin loss, appearing during the first day or two following the burn and often persisting for two or more weeks. These inclusions have been shown to originate within the cell, and are more numerous in younger forms of the myeloid series.³⁹

In the May-Hegglin anomaly, Döhle bodies are a consistent rather than transient finding, and are larger, more discrete, and occur in a much larger percentage of cells. They usually measure one to three μ in diameter and are quite prominent. Special staining technics have shown them to consist largely of RNA.^{5,6} Methyl green pyronin Y stains the cytoplasmic patches pink; if the unstained peripheral smear is first incubated with ribonuclease and then stained, the Döhle bodies no longer stain with pyronin, confirming their RNA content.^{5,40}

Easton and Fessas studied Döhle bodies in a variety of conditions, and concluded that there was a close structural relationship between the Döhle bodies found in the May-Hegglin anomaly and those found in association with various infections, a high proportion of RNA being present in both. They also noted that approximately half of their infectious disease patients who had Döhle bodies also had a transient thrombopenia, and thus such cases might con-

ceivably be confused with the May-Hegglin anomaly.³⁸ Such was probably the case in a 45 year old patient reported by Leitner et al., who died with massive purpura and sepsis.⁴¹ Although reported as a case of Hegglin's anomaly, the patient's Döhle bodies and thrombopenia were probably acute acquired infectious phenomena.

Electron microscopy of sectioned May-Hegglin leukocytes in our case and in two previous reports have shown the "Döhle bodies" to be cytoplasmic regions which lack specific granules.^{12,13} These patches are distinct from the remainder of the cytoplasm. They consist of small granules (200 Å in diameter) which are probably glycogen, amorphous homogeneous densities, and fine electron-dense fibrils of variable lengths which are thought to represent ribosomes.

Whether the May-Hegglin leukocytes function normally is still not entirely clear. Most evidence suggests that they do, in that none of the persons reported to date have had increased incidence of infections, and Rebuck skin window tests were said to be normal in the family reported by Petz et al.⁴ However, Rebuck et al. described leukocyte dysfunction at the inflammatory site in one person. This consisted of a loss of the cytoplasmic inclusion following migration of the leukocytes into the inflammatory site, and seeming impairment of phagocytic activity.⁴²

Bleeding Manifestations and Coagulation Studies

The only clinical abnormality reported in the May-Hegglin anomaly has been a bleeding tendency (in approximately one-fourth of the cases reported). This no doubt reflects at least in part the thrombopenia which occurs to some degree in the majority of persons with this anomaly (Table 3); however some investigators have implicated a platelet thromboplastic function defect as well.^{4,14} Of 44 persons with the May-Hegglin anomaly in the literature, 12 have been described as having significant hemorrhagic manifestations.^{2,9,10,13} The most common types of bleeding are recurrent epistaxis, and purpura, each reported in nine instances.

There is apparently a variable expressivity in the number of platelets, even among affected members of a single family (as was the case in father and son reported here). While the platelet count may be normal, in the majority of cases reported there is some degree of thrombocytopenia (Table 3). The platelets show a marked degree of aniso- and poikilocytosis, with giant round platelets as well as cigar-shaped forms and some normal appearing ones. Platelet survival studies have been reported in three persons.^{8,13} All three had somewhat shortened platelet survival, including one who had had a splenectomy. In each instance where a bone marrow was done, adequate numbers of megakaryocytes were noted.^{6,9,13}

Coagulation tests have rarely been reported; however in our two patients and a few other sporadic reports, coagulation tests other than those reflecting platelet numbers or platelet thromboplastic function have been normal. Clot retraction is proportional to the platelet count, being absent or poor in persons who are severely thrombopenic. Similarly, prolonged bleeding times and posi-

Table 3.—Summary of All Reported Cases of May-Hegglin Anomaly

Author	Year	No. of Cases	Platelet Count	Bleeding Manifestations	Family Studies
May	1909	1	None mentioned	None	Not mentioned
Hegglin	1945	3	10,000-30,000	Purpura	Father & 2 sons affected
Scholer	1960	1	25,000-110,000	None	Not done
Petz	1960	3	Mild thrombopenia	None	2 brothers & 1 son
Oski	1962	3	1,000-220,000	Epistaxis, hematuria & purpura in one subject	Mother, son & daughter
Wassmuth	1963	13	Normal	None	13 members of one family of 3 generations—9 M, 4 F
Buchanan	1964	2	77,000	None	Mother & daughter
Hegglin	1964	3	80,000	Epistaxis	1 girl, 2 boys in one family
Holslaw	1964	1	40,000-80,000	Epistaxis, purpura	1 boy only (parents & brother normal)
Goudemand	1965	5	50,000-115,000	None	Mother, 2 sons, 2 daughters
Jordan	1965	2	38,000	None	Mother & daughter
Davis	1966	2	40,000-60,000	None	Brother & sister
Najejan	1966	4	40,000-100,000	Epistaxis, purpura	Child, mother, aunt & greatgrandmother
This report	1967	1*	100,000 and 328,000	None	Father & son
Total		44			

*Father previously mentioned in report by Petz, et al.,⁴ thus only one additional case.

tive tourniquet tests have been found in individuals with very low platelet counts.^{11,13}

Tests of platelet thromboplastic function are of greater interest. Abnormal prothrombin consumption was found in the families studied by Goudemand¹¹ and by Petz,⁴ and was found in the father studied by us on each of three separate occasions. His abnormally short serum prothrombin time was corrected by the addition of hemolysate, suggesting a platelet defect. His platelet count of 100,000/mm.³ is not sufficiently low to account for the abnormal prothrombin consumption, thus a platelet thromboplastic function defect seemed likely. This was substantiated by a significant lag in the thromboplastin generation test when the father's platelets were tested in concentrations of 125,000/mm.³ and 250,000/mm.³, but not in higher concentrations. Petz et al.⁴ also reported "moderately deficient" platelet thromboplastic activity in three persons with the May-Hegglin anomaly. Nevertheless one must have strong reservations about the physiologic importance of these results. The study of platelet thromboplastic activity is difficult to standardize, and interpretation of results is always open to question.

Electron microscopy of sectioned platelets has been described in three previous reports.¹²⁻¹⁴ As in the father studied by us, no structural abnormalities were noted other than increased size. However, electron microscopic observations of whole unsectioned platelets from one individual with the May-Hegglin anomaly were interpreted by Rebusk and coworkers as demonstrating abnormal viscous metamorphosis.¹⁴ Their observations of defective pseudopodial formation and lack of platelet spreading may account for defective release of platelet factor 3. The latter may be apparent only on testing at low concentrations of platelets, or clinically in persons who are moderately thrombopenic.

To date all persons with the May-Hegglin anomaly have been heterozygotes. Thus it is unknown whether the homozygous state would be associated with a more severe hemorrhagic disorder, as is the case in another rare hereditary condition characterized by giant platelets. First described by Bernard and Soulier and termed, "la dystrophie thrombocytaire hémorragipare congénitale,"⁴³ this disorder is apparently transmitted as an incompletely recessive autosomal trait. In addition to giant platelets, homozygotes have abnormal platelet thromboplastic function and a bleeding diathesis, while heterozygotes have a lesser number of giant platelets only.⁴⁴

Both father and son had normal chromosomes. This finding is significant in that the only other family in whom chromosome studies were done had a minor chromosome abnormality (a large acrocentric chromosome with a barely detectable short arm). However the finding of this abnormal chromosome in the other family members who did not have the May-Hegglin anomaly suggested that it was probably unrelated to the latter.⁷

SUMMARY

A father and son with the May-Hegglin anomaly were studied. Both were asymptomatic, although the father had a mild thrombocytopenia and a probable platelet thromboplastic function defect. Possible mechanisms for the

bleeding tendency observed in approximately one-fourth of the persons with this anomaly are discussed. The autosomal dominant mode of inheritance is again demonstrated, and both father and son were found to have normal chromosomes.

SUMMARIO IN INTERLINGUA

Esseva studiate un patre e su filio qui habeva le anormalitate de May-Hegglin. Le duo subjectos esseva asymptomatic, ben que le patre habeva un leve thrombocytopenia e un probabile defecto de function thromboplastic in le plachettas. Mechanismos possibile pro le tendentia sanguinatori observate in approximativemente un quarto del personas con iste anormalitate es discutite. Le modo de hereditate a dominantia autosomal es demonstrate de novo, e tanto in le patre como etiam in le filio normalitate chromosomal esseva establite.

ACKNOWLEDGMENT

We are indebted to Dr. Thomas Petz for allowing us to study him and his sons.

REFERENCES

1. May, R.: Leukocyteninschlusse. *Deutsch Arch. Klin. Med.* 96:1-6, 1909.
2. Hegglin, R.: Simultaneous constitutional changes in neutrophils and platelets. *Helv. Med. Acta* 12:439-440, 1945.
3. Scholer, V. H., Imhof, H., and Schnös, M.: Beobachtungen an einem weiteren Träger der May-Hegglin'schen Anomalie der Leukozyten und Blutplättchen. *Schweiz. Med. Wschr.* 90:1269-1273, 1960.
4. Petz, A., Smith, I., and Nelson, N.: The May-Hegglin anomaly: A study of three cases (Abstract) *Clin. Res.* 8:215, 1960.
5. Wassmuth, D. R., Hamilton, H. E., and Sheets, R. F.: May-Hegglin anomaly. *J. Am. Med. Assoc.* 183:737-740, 1963.
6. Oski, F. A., Naiman, J. L., Allen, D. M., and Diamond, L. K.: Leukocyte inclusions—Döhle bodies—associated with platelet abnormality (the May-Hegglin anomaly). *Blood* 20:657-667, 1962.
7. Buchanan, J. G., Pearce, L., and Wetherly-Mein, G.: The May-Hegglin anomaly. A family report and chromosome study. *Brit. J. Haemat.* 10:508-512, 1964.
8. Davis, J. W., and Wilson, S. J.: Platelet survival in the May-Hegglin anomaly. *Brit. J. Haemat.* 12:61-65, 1966.
9. Hegglin, R., and Gross, R.: Anomalie Hegglin-May. *Schweiz. Med. Wschr.* 94:1357-1364, 1964.
10. Holsclaw, D. M.: Hegglin anomaly associated with glossitis, pharyngitis, and muscular hypotonia. *Proc. Roy. Soc. Med.* 57:835-836, 1964.
11. Goudemand, M., Parquet-Gervey, A., Hutin, A. et Vivier, E.: Les plaquettes dans l'anomalie de May-Hegglin. *Hemostase* 5: 241-249, 1965.
12. Jordan, S. W., and Larsen, W. E.: Ultrastructural studies of the May-Hegglin anomaly. *Blood* 25:921-932, 1965.
13. Najean, Y., Schaison, G., Binet, J. L., Dresch, C., and Bernard, J.: Le Syndrome de May-Hegglin. *Presse Med.* 74:1649-1652, 1966.
14. Rebuck, J. W., Riddle, J. M., Brown, M. G., Johnson, S. A., and Monto, R. W.: Volumetric and ultrastructural studies of abnormal platelets. In Johnson, S. A., Monto, R. W., Rebuck, J. W., and Horn, R. C., Jr., (Eds.): *Blood Platelets*. Boston, Little, Brown and Co., 1961, p. 542-550.
15. Sabatini, D. D., Bensch, L., and Barnett, R. J.: Cytochemistry and electron microscopy. The preservation of cellular ultrastructure and enzymatic activity by aldehyde fixation. *J. Cell. Biol.* 17:19-58, 1933.
16. Millonig, G.: Advantages of a phosphate buffer for OsO₄ solutions in fixation. *J. Appl. Phys.* 32:1637, 1961.
17. Palade, G. E.: A study of fixation for electron microscopy. *J. Exp. Med.* 95:285-297, 1952.
18. Pease, D. C.: *Histological Techniques for Electron Microscopy*. New York, Academic Press, Inc. 1964, Pg. 32.
19. Rytter, A., and Kellenberger, E.: L'inclusion au polyester pour ultramicrotomie. *J. Ultrastruct. Res.*, 2:200-214, 1958.
20. Reynolds, E. S.: The use of lead ci-

trate at high pH as an electron opaque stain in electron microscopy. *J. Cell. Biol.* 17:208-212, 1963.

21. Caen, J. P., Castaldi, P. A., Leclerc, J. C., Inceman, S., Larrieu, M. J., Probst, M., and Bernard, J.: Congenital bleeding disorders with long bleeding time and normal platelet count. *Am. J. Med.* 41:4-26, 1966.

22. Zucker, M. B., and Borrelli, J.: Viscous metamorphosis, clot retraction and other morphologic alterations of blood platelets. *J. Appl. Physiol.* 14:575-580, 1959.

23. Spaet, T. H., and Zucker, M. B.: Mechanism of platelet plug formation and role of adenosine diphosphate. *Amer. J. Physiol.* 206:1267-1274, 1964.

24. Zucker, M. B., and Borrelli, J.: Platelet clumping produced by connective tissue suspensions and by collagen. *Proc. Soc. Exper. Biol. Med.* 109-779-787, 1962.

25. Salzman, E. W.: Measurement of platelet adhesiveness. A simple *in vitro* technique demonstrating an abnormality in von Willebrand's disease. *J. Lab. Clin. Med.* 62:724-735, 1963.

26. Borchgrevink, C. F.: A method for measuring platelet adhesiveness *in vivo*. *Acta Med. Scand.* 168:157-164, 1960.

27. Zucker, M. B., Pert, J. H., and Hilgartner, M. W.: Platelet function in a patient with thrombasthenia. *Blood* 28:524-534, 1966.

28. Ivy, A. C., Shapiro, P. R., and Melnick, P.: Bleeding tendency in jaundice. *Surg. Gynec. Obst.* 60:781-784, 1935.

29. Lee, R. I., and White, P. D.: A clinical study of the coagulation time of blood. *Amer. J. Med. Sci.* 145:495-503, 1913.

30. Quick, A. J.: The determination of prothrombin by the method of Quick. In: *Transactions of the First Conference on Blood Clotting and Allied Problems of the Josiah Macy, Jr. Foundation*, 1948. New York: J. E. Flynn, ed., 1948, P. 170-172.

31. Quick, A. J.: The prothrombin consumption time test. *Amer. J. Clin. Path.* 45:105-109, 1966.

32. Quick, A.: Hemolysate prothrombin consumption time: a new test for thromboplastic coagulation defects. *J. Lab. Clin.*

Med. 57:290-299, 1961.

33. Heimburger, N. and Schwick, G.: Die fibrinagar-elektrophorese. I. Beschreibung der methode. *Thromb. Diath. Haemorrh.* 7:432-443, 1962.

34. Döhle, V.: Leukocyteinschlüsse bei scharlach. *Zbl. Bakt.* 61:63-68, 1912.

35. Kilmer, J. A.: Leukocyte "inclusion bodies" with special reference to scarlet fever. *Amer. J. Dis. Child.* 4:1-6, 1912.

36. Macewen, W.: An investigation concerning Döhle's leukocyte "inclusion bodies" in scarlet fever and other diseases. *J. Path. Bact.* 18: 456-461, 1913.

37. Bachman, R. W. and Lucke, B. H.: The differential blood count, the Arneth formula and Döhle's inclusion bodies in pulmonary tuberculosis. *New York J. Med.* 107: 492-495, 1918.

38. Easton, J. A. and Fessas, C.: The incidence of Döhle's bodies in various diseases and their association with thrombocytopenia. *Brit. J. Haemat.* 12:54-60, 1966.

39. Weiner, W. and Topley, E.: Döhle bodies in the leukocytes of patients with burns. *J. Clin. Path.* 8:324-328, 1955.

40. Hansson, H., Linell, F., Nilsson, L. R., Söderhjelm, L., and Undrity, E.: Die Chediak-Steinbrinck—Anomalie Resp. Erbliche Konstitutionelle Reisengranulation der Leukozyten in Nordschweden. *Folia Haemat. N. S.* 3:152-196, 1959.

41. Leitner, S. J., Neumark, E., and Heeres, P. A.: Panmyelopathy with Döhle bodies, thrombocytopenia and erythroblastosis (Hegglin's syndrome). *Acta Haemat.* 11:321-327, 1954.

42. Rebusch, J. W., Barth, C. L., and Petz, A. M.: New leukocyte dysfunction at the inflammatory sites in Hegglin's, Hurler's and Pelger-Huet anomalous states. *Fed. Proc.* 22:427, 1963.

43. Bernard, J., and Soulier, J. P.: Sur une nouvelle variété de dystrophie thrombocytaire hémorragipare congénitale. *Sem. Hôp. Paris* 24:3217-3223, 1948.

44. Kanoka, B., Niewiarowski, S., Ostrowski, L., Poplawski, A., and Prokopowicz, J.: Macrothrombocytic thrombopathia. Clinical, coagulation and hereditary aspects. *Thromb. Diath. Haemorrh.* 10:88-100, 1963.